

## **Case Report**

### **A DUAL NEUROLOGICAL INSULT: IPSILATERAL SUBACUTE SUBDURAL HEMATOMA AND ISCHEMIC STROKE IN AN ELDERLY PATIENT WITH CONTRALATERAL WEAKNESS.**

Omair Farooq<sup>1</sup>, Fiza Ashfaq<sup>2</sup>, Siddiqua Rehman<sup>3</sup>

#### **Abstract:**

This case report discusses a rare occurrence of simultaneous subacute subdural hematoma (SDH) and ischemic stroke in a 95-year-old male patient with a history of chronic obstructive pulmonary disease (COPD) and chronic kidney disease (CKD). The patient presented with contralateral weakness and a series of diagnostic challenges. This report underscores the complexities in the diagnosis and management of these concurrent neurological insults. A detailed analysis of the clinical findings, treatment strategies, and prognostic considerations is provided, with reference to existing literature on similar cases.

**Keywords:** Subdural hematoma, ischemic stroke, elderly, concomitant pathology, stroke management, anticoagulation, multidisciplinary approach, neuroimaging

**doi:** <https://doi.org/10.51127/JAMDCV06I04CR01>

#### **How to cite this:**

Farooq O, Rehman S, Ashfaq F. A Dual Neurological Insult: Ipsilateral Subacute Subdural Hematoma & Ischemic Stroke in an Elderly Patient with Contralateral Weakness. JAMDC, 2024; 6(4): 170-174

doi: <https://doi.org/10.51127/JAMDCV06I04CR01>

## **INTRODUCTION**

Ischemic stroke and subdural hematomas (SDHs) are common yet distinct neurological conditions, frequently observed in the elderly. SDHs often result from traumatic brain injury (TBI), such as falls, leading to blood accumulation between the dura and arachnoid mater.<sup>1</sup> Presentations can range from acute SDHs, which require immediate neurosurgical intervention,<sup>2</sup> to subacute or chronic SDHs, which may manifest over weeks to months, particularly in individuals over 65 years of age.<sup>3,4</sup> Conversely, ischemic strokes typically arise

from thromboembolic events, often associated with atherosclerosis or cardiac emboli.<sup>5</sup> Symptomatology in ischemic strokes varies based on the affected vascular territory and extent of ischemia.<sup>6</sup> The concurrent occurrence of SDH and ischemic stroke is rare but poses significant diagnostic and therapeutic challenges, especially in anticoagulated patients, necessitating tailored management strategies for dual pathologies.<sup>7</sup>

65 years of age present with gradual symptoms over weeks to months.

Ischemic strokes most commonly occur due to thromboembolic events caused by atherosclerotic plaques in the carotid or vertebral arteries, or cardiac thrombi. Clinical presentation and symptom progression depend on the location, extent of ischemia, and the affected vascular territory.

#### **CASE PRESENTATION:**

A 95-year-old male with a medical history of

<sup>1</sup> Asst. Prof. Medicine, Farooq Hospital (WW), Lahore

<sup>2</sup> MO, Surgical ICU Dept, Farooq Hospital (WW), Lahore

<sup>3</sup> MO, Medical ICU Dept, Farooq Hospital (WW), Lahore

Date of Submission: 02-12-2024

Date of Review: 04-12-2024

Date of Acceptance: 10-12-2024

Chronic Obstructive Pulmonary Disease (COPD) and Chronic Kidney Disease (CKD) stage 3 presented to the Emergency Department at Farooq Hospital, Westwood. He complained of shortness of breath, confusion, left-sided body weakness, and slurred speech. The symptoms had progressively worsened over the past 7 days.

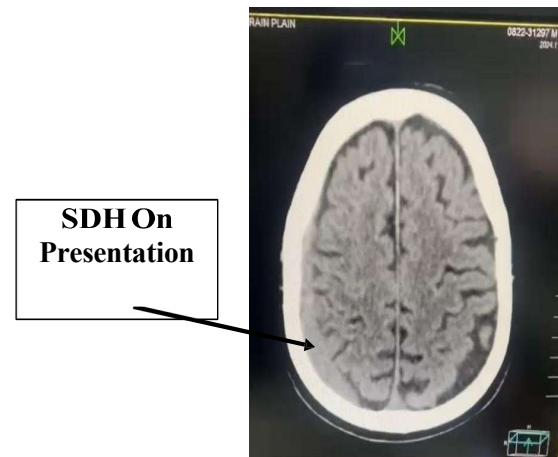
Patient presented with the history of fall. However, no symptoms were noted immediately following the incident. Seven days post-injury, the patient developed fluctuating left-sided weakness and disorientation. The weakness was intermittent in the upper and lower limbs which was progressively worsening. Over time, the patient became unable to bear weight or stand independently.

A neurological examination conducted on Day 1, the patient exhibited left-sided weakness, with muscle power rated at 1/5 in both the left upper and lower limbs. A positive Babinski's sign was noted on the left side. The Glasgow Coma Scale (GCS) score was 8/15, with an eye response of E2, a verbal response of V2, and a motor response of M4.

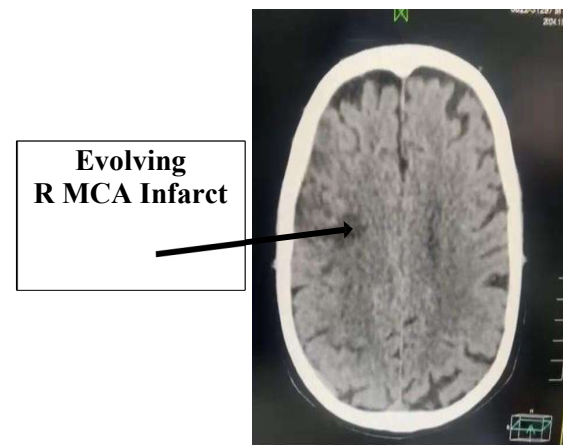
The patient presented with fever and coarse crepitations throughout the chest. Supplemental oxygen was required, administered at 2–3 liters via nasal cannula. The pulse was irregular, and an electrocardiogram (ECG) revealed new-onset atrial fibrillation.

A CT brain scan revealed isodense concavity on the right side, which is indicative of a subacute subdural hematoma (Figure 1). Additionally, an evolving infarct was noted in the right middle cerebral artery (MCA) territory (Figure 2) (Figure 4). Importantly, no mass effect or herniation was observed.

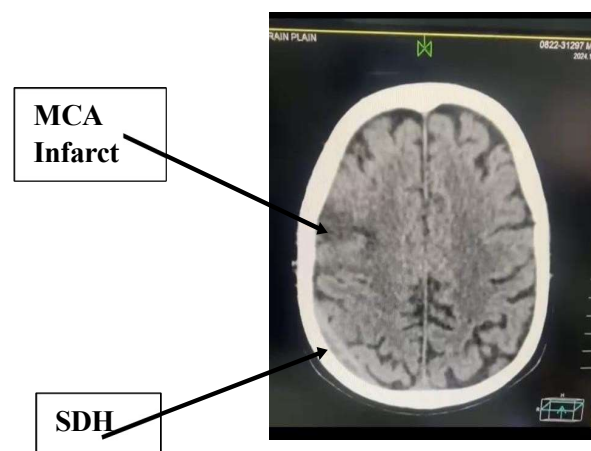
The CT carotid angiography confirmed the presence of an atherosclerotic plaque in the right internal carotid artery, causing 50% stenosis. This was identified as the cause of the ischemic stroke. The echocardiogram revealed severe pulmonary hypertension (PASP 60 mmHg) and moderate tricuspid regurgitation. The likely etiology of these findings was the patient's underlying COPD. The patient's blood work showed an elevated white cell count, indicating an acute infective exacerbation of COPD.



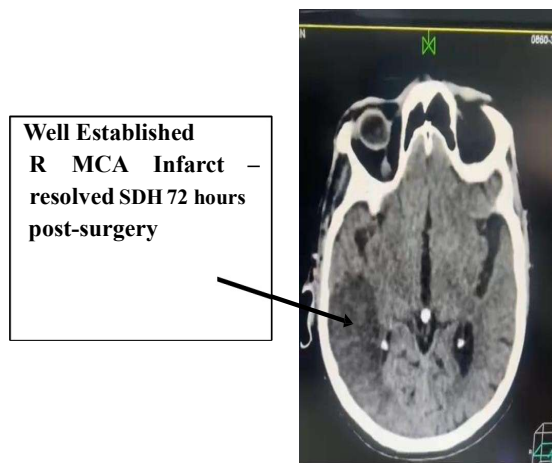
**Figure 1:** An isodense concavity (subacute subdural hematoma) on the right side.



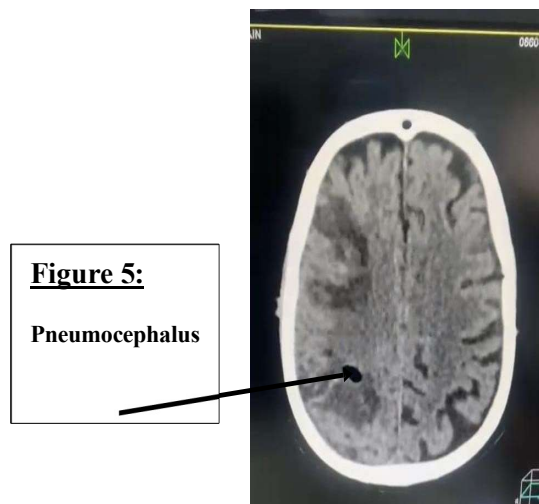
**Figure 2:** Evolving infarct in Right Middle Cerebral Artery (MCA)



**Figure 3:** Right MCA Infarct along with SDH



**Figure 4:** MCA infarct post-surgery



**Figure 5:** Resolved SDH with Pneumocephalus post -Surgery

The coagulation profile was normal. The patient was admitted to the ICU for close monitoring. Atrial fibrillation was treated with a 300 mg STAT dose of amiodarone, which successfully reverted the rhythm to normal sinus rhythm. A 72-hour Holter monitor showed no significant findings. CT findings suggested that the stroke had occurred 24–48 hours prior, with symptoms persisting for more than 72 hours. This placed the patient outside the

window for thrombolysis (tPA). Thrombolytics were not used due to the patient's advanced age (95 years) and the concurrent presence of a right-sided subdural hematoma, which increased the risk of bleeding.

A burr hole craniotomy was performed to evacuate the subdural hematoma. The procedure resulted in the complete resolution of the subdural hematoma.

To manage the acute infective exacerbation of COPD, the patient was administered IV antibiotics (Imipenem, Moxifloxacin) and IV steroids for inflammation control. Additionally, nebulization with ipratropium and beclomethasone was provided.

The patient was started on a calcium channel blocker, Diltiazem, to manage the pulmonary hypertension.

A coordinated care approach involving neurosurgery, neurology, pulmonology, and cardiology was implemented to provide comprehensive management for the patient.

## DISCUSSION

The concurrent occurrence of ipsilateral subacute subdural hematoma (SDH) and ischemic stroke in elderly patients, presenting with contralateral weakness, is a rare and complex clinical scenario. Such cases pose significant diagnostic and therapeutic challenges, particularly in individuals on anticoagulation therapy.

The current case presented unique challenges in managing an elderly patient with concurrent right-sided subdural hematoma and ipsilateral ischemic stroke, complicated further by comorbidities such as atrial fibrillation, COPD, and severe pulmonary hypertension. The simultaneous presence of SDH and ischemic stroke highlighted the complexities in diagnosis and treatment, particularly in elderly patients with multiple coexisting conditions.

The decision to withhold thrombolytics in the present case, given the patient's advanced age,

the risk of hemorrhagic complications from SDH, and the fact that the patient was outside the thrombolysis window, demonstrates the need for individualized, risk-averse management strategies. The successful burr hole craniotomy for SDH evacuation resulted in the resolution of neurological deficits.

Postoperatively, the patient required ventilatory support due to a severe COPD exacerbation. Antibiotics and steroids helped manage his respiratory infection and inflammation, while calcium channel blockers addressed his pulmonary hypertension.

### OUTCOME AND FOLLOW-UP

The patient remained hospitalized for 10 days. His GCS improved from 8/15 on presentation to 15/15 postoperatively. Despite some persistent weakness in his cough and gag reflex, his overall neurological function improved significantly. A nasogastric tube (NGT) was used for feeding during the initial 7 days post-surgery, which was removed upon discharge following improvement in his cough and gag reflex.

The patient was discharged with a follow-up visit in the outpatient clinic, where he demonstrated continued improvement.

One such case was presented by Strahlen et al.<sup>8</sup> who reported an 83-year-old male on apixaban therapy who developed a right parietal SDH and subsequent ipsilateral ischemic stroke, highlighting the intricacies of managing dual pathologies in anticoagulated patients.

The management included reversing apixaban with specific agents to prevent hematoma expansion, close neurological monitoring, and surgical evacuation of the subacute subdural hematoma to relieve intracranial pressure. Thrombolysis was contraindicated for the ischemic stroke, with supportive care provided instead. Post-stabilization, the patient underwent rehabilitation, and a careful risk-benefit assessment was conducted for resuming anticoagulation therapy to prevent further thromboembolic events.

These cases underscore the importance of

comprehensive neurological assessment and advanced imaging techniques in elderly patients presenting with atypical neurological deficits. A multidisciplinary approach is essential to navigate the challenges of anticoagulation management and to optimize patient outcomes in such complex clinical scenarios.

Gonzalez et al.<sup>9</sup> emphasized that elderly patients with ischemic stroke and multiple underlying conditions benefit from coordinated care involving specialists from various fields, including neurology, pulmonology, cardiology, and surgery. This approach improves the overall management and outcome by addressing the complex interactions between different medical conditions.

In this case, the collaborative efforts of neurosurgery, neurology, pulmonology, and cardiology teams ensured comprehensive care and targeted interventions, helping to stabilize the patient and address each of the complicating factors.

### CONCLUSION

This case highlights the importance of a multidisciplinary approach when managing complex, intersecting pathologies in elderly patients. The successful management of dual neurological insults—subdural hematoma and ischemic stroke—was made possible through tailored treatment strategies that involved neurosurgery, neurology, pulmonary medicine, and cardiology. Future research should focus on refining management strategies for patients with multiple comorbidities and simultaneous neurological insults.

### CONFLICT OF INTEREST

None

### AUTHOR CONTRIBUTION

**OF:** Concept, critical review, proof reading

**SR:** Drafting of literature review

**FA:** Compilation of data and discussion

## REFERENCES

1. Balachandar A, Carpani F, Del Campo M, Mandell D. Subdural Hematoma-Induced Cortical Perforator Thrombosis Causing Ischemic Strokes. *Stroke*. 2022 Aug;53(8):e381-2. doi:10.1161/Strokeaha.122.039482.
2. Abe M, Udono H, Tabuchi K, Uchino A, Yoshikai T, Taki K. Analysis of ischemic brain damage in cases of acute subdural hematomas. *Surg Neurol*. 2003 Jun;59(6):463-71. doi:10.1016/S0090-3019(03)00078-8.
3. Kocaman U, Demirci G, Yilmaz A, et al. Acute subdural hematoma associated with ischemic stroke: a case report and review of the literature. *Br J Neurosurg*. 2016.
4. Sugiyama H, Tsutsumi S, Watanabe A, Nonaka S, Okura H, Ishii H. Simultaneous presentation of subcortical hemorrhage, subdural hemorrhage, and cerebral infarct in a hemiplegic patient. *Radiol Case Rep*. 2022May;17(5):1376-9. doi:10.1016/j.radcr.2022.02.016.
5. Fukui S, Imazeki R, Amano Y, et al. Common and specific risk factors for ischemic stroke in the elderly: Differences based on type of ischemic stroke and aging. *J Neurol Sci*. 2017 Sep;380:85-91. doi:10.1016/j.jns.2017.07.001.
6. Al-Thawwab N, Alfaraj D, Alenezi A, et al. Delayed recognition, surgical dilemmas, and complications: A case report of acute-on-chronic subdural hematoma. *Cureus*. 2023 Dec;15(12):e 50610. doi:10.7759/cureus.50610.
7. Kocaman U, Demirci G, Yilmaz A, et al. Acute subdural hematoma associated with ischemic stroke: a case report and review of the literature. *Br J Neurosurg*. 2016.
8. Strahnen C, Meyer L, Fischer D, Foerch C, Seipelt M. Concurrent low-volume subdural hematoma and ipsilateral ischemic stroke presenting as capsular warning syndrome: a complex case with anticoagulation dilemma and dual pathology. *Case Rep Neurol Med*. 2023; 2023:1234567. doi:10.1155/2023/1234567
9. Gonzalez, H. M., et al. (2015). Multidisciplinary management of elderly patients with ischemic stroke. *Journal of Clinical Neurology*, 11(4), 355-361.